

Patient stratification using point of care biomarkers in dry eye disease

Abstract

With changes in lifestyle, such as the increasing use of digital screens and rising demand for refractive surgery, dry eye disease has become increasingly prevalent in recent times. While we are equipped with a number of diagnostic modalities and a myriad of treatment forms, ranging from topical medication to procedural therapies, the condition remains an enigma in terms of varied patient satisfaction. An understanding of the molecular basis of a disease may open up new avenues in the customization of its treatment. We attempt to simplify this in the form of a stepwise protocol to incorporate biomarker assays in dry eye management.

Keywords: Biomarker assay, dry eye, tear fluid biomarkers

The prevalence of a condition, the expenditure it incurs, and its impact on the patient's quality of life may, altogether, be considered a tolerable estimation of its burden on the global healthcare system. In this regard, dry eye disease has been noted to have a significant bearing in the field of ophthalmology. The prevalence of the condition across the world has been estimated to be between 5% and 50%, with the large disparity being attributed to differences in study populations, geographical influence, method of assessment, and even variations in the definition. To provide an estimation of the economic burden of the condition, the total annual cost for management is projected to be USD 3.84 billion in the United States and USD 0.15 million in Singapore, considering the losses incurred in terms of direct spending on medical care as well as the impact on loss of productivity.

From a clinician's point-of-view, consequences on a patient's quality of vision and life are the most easily assessed, and the most significant determinators of the success of the treatment instituted. Approximately 60% of dry eye disease patients have been estimated to report reduced quality of life in daily activities and leisure pursuits, and this is comparable

to the decrease in quality of life reported for patients of angina pectoris. Reduced efficiency at work has been stated by 38% of patients and may be an added incumbrance to the existing economic burden of treatment.

While current modes of assessment and management of dry eye disease rely largely on patient-reported symptoms and clinical examination, these means may not necessarily give an accurate or thorough picture of the condition for more personalized and effective management. This article focuses on the need for more comprehensive methods of dry eye disease examination with the utilization of non-invasive tear fluid-based biomarkers for a more target-specific approach to treatment.

Need for Comprehensive Evaluation

Dry eye disease presents a unique conundrum to ophthalmologists, in that the symptoms and signs—or in other words, the subjective and objective clinical findings of dry eye disease—do not necessarily correlate. Patients reporting severe symptoms, suggestive of the condition, may not display proportionately severe clinical signs, whereas those with significant clinical features may report mild to no symptoms. Moreover, a considerable overlap exists between the clinical presentations of a wide variety of ocular surface conditions, including dry eye disease, ocular surface infections, and allergies. A meticulous examination is necessitated but may not always be adequate to arrive at an accurate diagnosis, and each condition and at times each patient mandates a distinct treatment. In the event of an incorrect diagnosis, a medication used to treat the latter two, such as antiallergic drugs and epitheliotoxic antibiotics, may actually exacerbate the former.

Evolution of Modalities in Dry Eye Disease Evaluation

Traditional examination of dry eye disease includes detailed history-taking with emphasis on understanding ocular and systemic risk factors; detailed clinical evaluation encompassing examination of the eyelids, including

assessment of blink rate, lid closure, lid congruity, lid margin for evidence of meibomian gland disease; examination of the conjunctiva and ocular surface with vital staining such as fluorescein or lissamine green; and examination of the tear film, including tear film break-up time (TBUT), tear film height and tear secretion tests such as Schirmer's tests.

With the advancement in technology, imaging modalities have developed that aid objective assessment of dry eye disease. These include non-invasive tear break-up time (NIBUT), tear interferometry, non-contact infrared meibography, and *in vivo* confocal microscopy. Tear osmolarity is also a recently available option, with commercial machines that are Food and Drug Administration (FDA)-approved for point-of-care use; however, high variation in measurements limits its potential to be used as an objective biomarker at present.

Role of Biomarkers in Dry Eye Disease

In recent decades, the use of tear film biomarkers in the diagnosis and management of dry eye disease has garnered increasing scientific and clinical interest, not merely due to their role in the pathogenesis of ocular surface damage but also owing to the technical feasibility of the collection of tear samples. As per the TFOS DEWS II Clinical Trial Design Report, validation of reliable biomarkers of disease as well as proposed composite indices as outcome parameters is an ongoing need. Studies have established strong correlations between certain cytokines, including interleukin-6 (IL-6), tumor necrosis factor-alpha (TNF- α), interleukin-17 (IL-17A), and dry eye disease. Novel therapeutic agents have been developed for dry eye disease that block the interaction of intercellular adhesion molecule (ICAM-1) with lymphocyte function-associated antigen 1 (LFA1) and subsequent cellular effects that are associated with dry eye disease pathogenesis. Matrix metalloproteinase-9 (MMP-9) testing is also a validated tool for the identification of ocular surface inflammation and may facilitate the decision to initiate anti-inflammatory medication in these patients. A significant correlation between increased MMP-9 levels and symptoms and signs of dry eyes, such as decreased TBUT, ocular surface staining, low Schirmer's test values, and meibomian gland disease

(MGD), has also been noted.

As a diagnostic marker, tear film biomarkers may not only be a more sensitive means of assessment as compared to tests such as Schirmer's test but may also be better indicators of disease severity as compared to ocular surface staining. Moreover, given the established role of certain drugs against specific markers, such as topical corticosteroids and cyclosporine A in the suppression of MMP-9, they may guide targeted therapy and simplify the process of monitoring response to treatment.

Roy *et al.* described an ideal biomarker to be one that is relevant to the clinical setting and disease severity, reproducible, and easy and economical to use. However, present methods of measurement of tear film biomarkers, such as enzyme-linked immunosorbent assay, multiplex bead-based analysis, proteomic technology, or a combination thereof, are typically performed in the laboratory setting and involve high cost and utilization of different instruments.

The commercialization of point-of-care MMP-9 immunoassay devices has vastly simplified this process by providing a 10-min in-office immunoassay that detects abnormally elevated levels of MMP-9 (>40 ng/mL). A positive test indicated confirmation of accompanying inflammation in dry eye disease, thereby leading to more targeted therapeutic intervention.

However, protein biomarker studies have revealed that it is not merely a single protein, but a group of biomarkers that are altered in individuals affected with dry eye disease. Being a disease of multifactorial etiology, screening individual targets may not necessarily provide a complete picture of the condition, thereby reducing the diagnostic power of the instrument. Moreover, quantification of biomarkers may enable monitoring of response to therapy, as opposed to a test such as the InflammADry, which provides only a binary response.

To overcome these limitations of an otherwise expedient platform, we developed a point-of-care immunoassay device for the quantification of select biomarkers.

Point-of-Care Immunoassay Device for Clinical Use

We adapted an existing laboratory multiplex analysis platform to simplify the complex and time-consuming single analyte ELISA process into a simple, customized, 90-min rapid test for clinical diagnostic use. In our biomarker studies and published literature, we discovered the role of a few secreted inflammatory factors in ocular fluids associated with disease pathology and severity such as the role of IL-6, TNF- α , and IL-17A in dry eye disease; MMP-9 and pro-inflammatory interleukins (IL-1 β , IL-6, and IL-17A) in keratoconus and ocular surface inflammation; TNF- α in haze-predisposed patients; and vascular endothelial growth factor (VEGF) in retinopathy of prematurity. These factors were chosen based on their expected clinical importance in diagnosis, prognosis, monitoring potential, or the possibility of targeted treatment. Some factors were selected due to the availability of targeted therapeutic drugs in the market or clinical trials, such as the role of cyclosporine-A against MMP-9 and topical lifitegrast 5% solution against intercellular adhesion molecule (ICAM-1). The anti-inflammatory marker IL-10 was incorporated into the panel to understand the balance between the pro-inflammatory and anti-inflammatory markers. Thus, a microfluidic cartridge-based multiplex ELISA kit (Bio-M Pathfinder, NovoMol-Dx, India, a customized version of the Ella Automated ELISA system, BioTechne, Minnesota, USA) was customized for the analysis of the eight aforementioned biomarkers.

Guidelines for Patient Stratification using Point-of-Care Biomarker Assay

1. Clinical History

It is essential to elicit an exhaustive history of the patient's condition to identify any risk factors or conditions that may be perpetuating the same and also determine which patients require an in-depth analysis and

biomarker assay. Proper redressal of these pre-existing risk factors is essential in addition to treating dry eye disease. If there is suspicion of systemic disease, an appropriate referral may be directed to a physician or immunologist. Details about patient lifestyle also need to be elicited, such as the number of hours spent using digital screens and occupational exposure to radiation to institute appropriate patient education regarding these.

2. Patient Questionnaires

Several validated questionnaires, such as the Ocular Surface Disease Index (OSDI), Dry Eye Questionnaire (DEQ-5), and Impact of Dry Eye on Everyday Living (IDEEL), are available. They are also important tools to identify a discrepancy between clinical symptoms and signs.

3. Slit-lamp Examination

Examination using the slit lamp should ideally include examination of the lids to assess the blink rate, lid congruity, lid closure, and lid margin disease; examination of the conjunctiva and ocular surface by vital staining using fluorescein and lissamine green; examination of the tear film including the height and break-up time, as well as quantitative tests such as Schirmer's I and II tests. The strips used for performing the test may be collected for biomarker analysis if required, as in the procedure detailed below.

4. Imaging

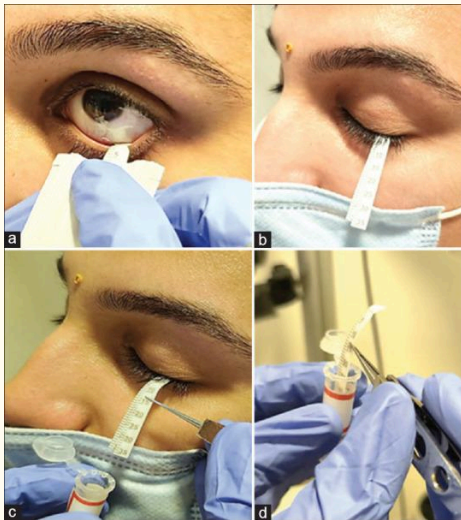
In case of discrepancy between signs and symptoms, the imaging modalities outlined earlier may supplement clinical diagnosis. For instance, the Non-invasive keratograph tear film break up time (NIKBUT) may serve to provide information about the tear film without the utilization of dyes. Infrared meibography may help identify gland dropout in patients with symptoms of dry eye but without any evidence of meibomian gland

dysfunction. In patients typically described as “pain without stain,” whose symptoms are disproportionately high as compared to their clinical signs, confocal microscopic features may be assessed—the presence of microneuromas may point toward neuropathic corneal pain, which is a separate entity requiring special care as per the TFOS DEWS II report.

5. Biomarker Analysis

When there is a discrepancy in the symptoms reported by the patient and the objective signs seen on clinical examination and imaging, biomarker analysis may supplement the diagnosis. This is performed by tear collection with the help of Schirmer’s strips, in the procedure detailed below.

Standardization of tear collection using Schirmer’s strips [[Fig. 1](#)]



[Figure 1](#)

(a) With due aseptic precautions, Schirmer’s strip is placed at the junction of the medial two-thirds and lateral one-third of the lower lid. (b). The strip is allowed

to wet for 5 min for collection of an adequate sample of tear fluid. (c). The strip is collected with a pair of sterile forceps, taking care to ensure no accidental contact with any other surface so that there is no contamination of the sample collected. (d). The strip is placed in a sterile Eppendorf tube for storage at -80°C and transportation

1. Ensure that the collection is performed while wearing sterile gloves.
2. Ensure that the technician does not directly touch Schirmer's strips while performing the procedure to avoid contamination of the sample.
3. Schirmer's strip must be bent at the preformed notch by 90 degrees and then placed into the conjunctival sac at the junction of the middle and lateral thirds.
4. Ensure that the paper is allowed to wet by capillary action for 5 min.
5. Collect the strips in sterile 1.5 mL microcentrifuge tubes from the fornix with a pair of sterile forceps to avoid contamination of the sample.

Loading the customized cartridge

1. Add 300 μL of extraction buffer solution to the tubes to elute the tears.
2. The tube is agitated for 5 min by manual shaking.
3. Add 50 μL of the resulting extract to each sample well of the customized cartridge for measurement of designated markers.
4. Add 1 mL of proprietary wash buffer to the designated buffer well.
5. Load the cartridge into the analyzer system. A dilution factor derived from individual patient wetting length is entered into the system, which helps standardize the levels of biomarkers across all wetting lengths. The system provides the measured value of the specific analyte based on the established internal references for each within a span of 90 min.

BESTT (biomarker-enabled specific targeted therapy) protocol

Based on the existing modalities available in the literature and our own clinical experience, we devised a protocol for stratifying these patients as per the markers that are elevated and for instituting the appropriate treatment. Our approach to these patients is outlined in the flowcharts provided

b]. The elevated inflammatory markers (single or multiple) were identified on the basis of tear biomarker analysis, with the reference cut-off values established from our own normative database. Patients with elevated MMP-9, a biomarker with an established role in dry eye disease, were further stratified based on the degree of elevation.

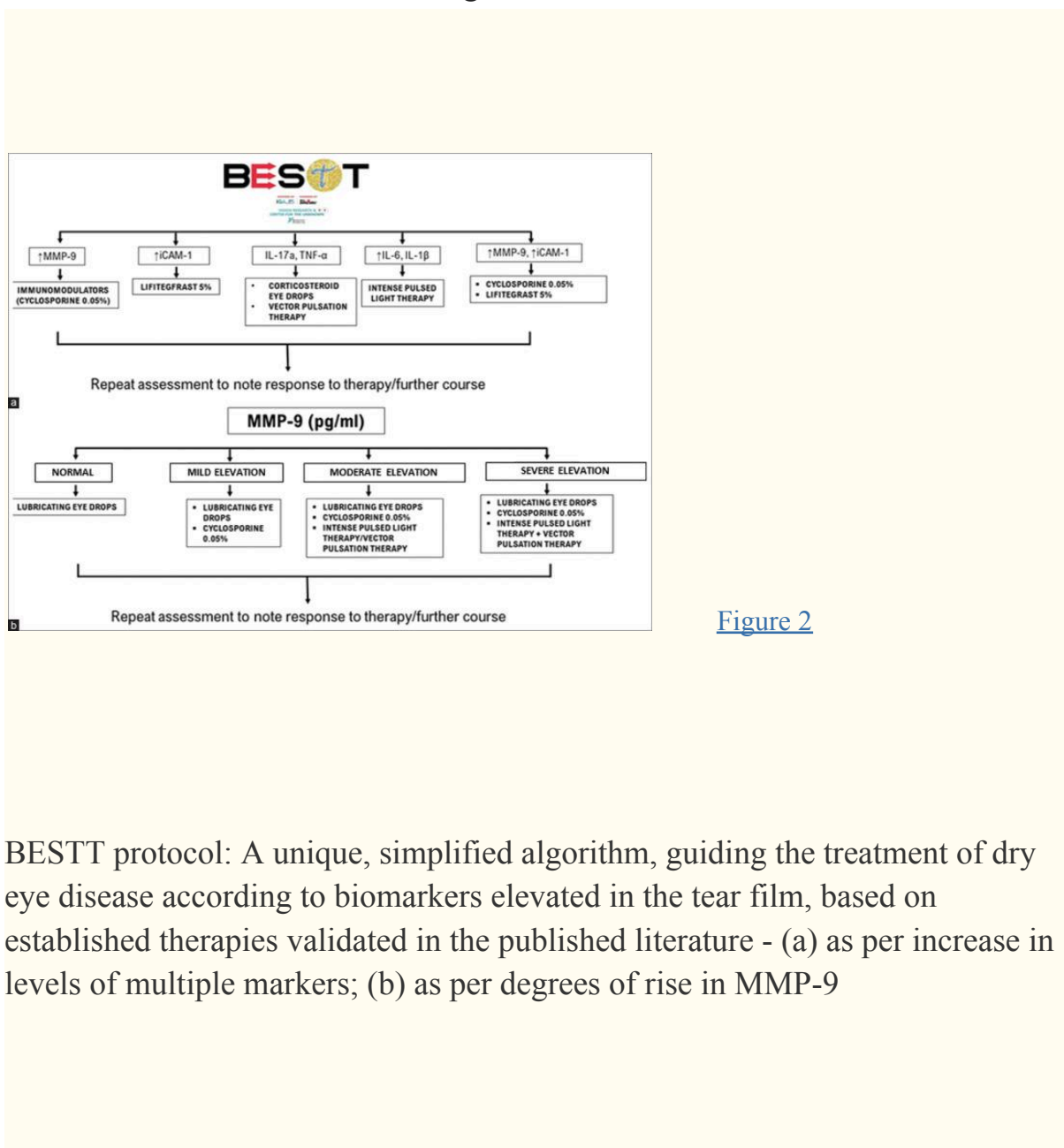


Figure 2

BESTT protocol: A unique, simplified algorithm, guiding the treatment of dry eye disease according to biomarkers elevated in the tear film, based on established therapies validated in the published literature - (a) as per increase in levels of multiple markers; (b) as per degrees of rise in MMP-9

The case series was approved by the institutional ethics committee and was conducted in accordance with the tenets of the Declaration of Helsinki (2013). Written informed consent was obtained from the participants before their inclusion in the analysis.

1. Elevated MMP-9 (>matched control cohort)

a. Mild elevation (>2-3 times of healthy controls)

It is recommended to treat these patients with topical cyclosporine A with a lubricating eye drop such as topical trehalose for a minimum of 3 months before reassessment.

The anti-inflammatory drug cyclosporine is known to reduce levels of MMP-9 in the tear fluid. It is also known to prevent the activation of T-cells and the production of inflammatory cytokines and demonstrates some benefits in increasing tear secretion. Additionally, topical trehalose has been shown to reduce tear levels of inflammatory cytokines more than carboxymethylcellulose-based lubricating eye drops, and would therefore play an adjuvant role in suppressing mild ocular surface inflammation.

To demonstrate this phenomenon with a case example, we present the case of a 30-year-old lady, who was a known case of keratoconus on regular follow-up at our institute. In one of her recent visits, she presented with several points of steepening on the corneal tomography report as compared to the last visit, along with loss of corneal thickness [[Fig. 3a](#)]. Biomarker analysis was performed on the collected tear sample, and she was noted to have mildly elevated levels of MMP-9 in both eyes [[Fig. 4a](#)]. We decided to keep her under observation while treating the ocular surface with a higher inflammatory profile with topical cyclosporine and trehalose. On her next follow-up visit after 6 months, a comparative analysis of corneal topography revealed stable keratometry and pachymetry values [[Fig. 3b](#)]. Moreover, the tear biomarkers were reassessed and she was noted to have reduced levels of MMP-9 [[Fig. 4b](#)].

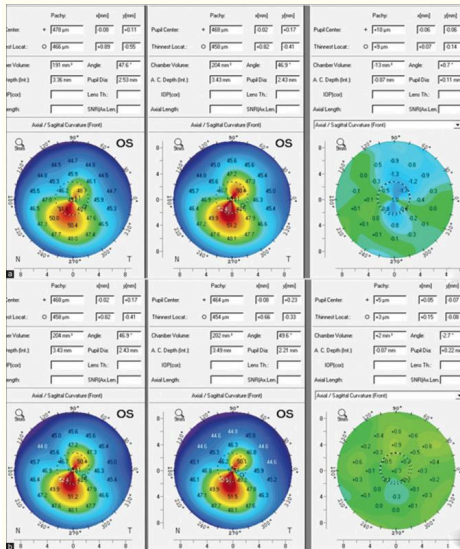


Figure 3

(a). Comparative topography showing more than three points of steeping in the cone area with 8 μ s of loss of pachymetry, indicating progression of keratoconus. (b). Comparative topography of the same patient after 6 months, demonstrating stable keratometry and pachymetry values with no evidence of progression

Test Parameter	Results		Test Parameter	Results	
	Right Eye	Left Eye		Right Eye	Left Eye
IL- 6	13.1	19.4	IL- 6	13.5	8.6
IL- 1b	2.6	1.7	IL- 1b	2.4	1.23
IL- 17 A	9.3	6.1	IL- 17 A	7.8	5.92
MMP 9	129180	161807	MMP 9	3830	6822
I CAM - 1	32062	34729	I CAM - 1	22231	30986
TNF - a	4.6	2.61	TNF - a	2.63	2.42
IL-10	0.387	0	IL-10	0.164	0.890
VEGF- A	203	320	VEGF- A	423	409

Figure 4

(a). Biomarker report of a patient of keratoconus with ongoing progression, demonstrating elevated levels of MMP-9 with a demonstrated role in keratoconus progression. (b). Repeat biomarker analysis showing dramatically reduced levels of MMP-9 in response to topical therapy with cyclosporine and trehalose, accompanied by stabilization of keratometry and pachymetry values

b. Moderate elevation (>3 times of healthy controls)

We recommend the use of procedural dry eye therapy in the form of vector pulsation therapy devices or intense pulsed light with low-level light therapy (IPL + LLLT) for dry eye disease with moderate elevation of MMP-9 levels in addition to topical treatment as prescribed. Vector pulsation therapy has been shown to reduce MMP-9 levels on the ocular surface of patients with dry eye disease, and has also led to improvement in measures such as tear fluid osmolarity, TBUT, and OSDI.

To illustrate this with a case example, a 38-year-old gentleman presented to the refractive service at our hospital for consultation regarding undergoing refractive surgery. He had no significant ocular complaints related to dry eye or systemic complaints, indicating any inflammatory predispositions to developing dry eye, nor did he report any relevant past ocular or systemic history.

On slit-lamp examination, there was no evidence of meibomian gland disease. As part of the routine screening before refractive surgery, he underwent corneal topography using a rotating Scheimpflug camera (Pentacam, Oculus Optikgeräte GmbH), assessment of corneal biomechanics using Corneal Visualization Scheimpflug Technology (Corvis ST) and epithelial mapping using MS39 anterior segment optical coherence tomography. While the topography and biomechanics were reported to be within normal limits, the epithelial mapping revealed significant irregularity in the thickness map [Fig. 5a].

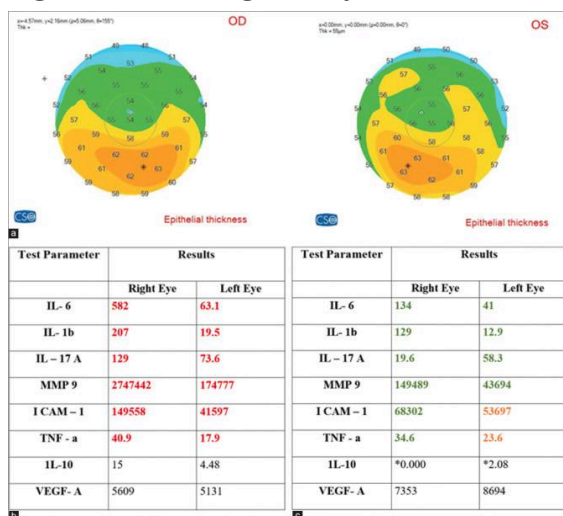


Figure 5

(a). Epithelial maps of the right and left eyes of a pre-refractive surgery patient, demonstrating irregular surface epithelium, possibly a result of underlying dry eye or ocular surface inflammation. (b). Biomarker report of the patient showing high levels of MMP-9 along with other pro-inflammatory markers, indicating ongoing surface inflammation. (c). Biomarker report of the same patient showing reduced levels of most pro-inflammatory markers 3 weeks after a single session of thermal pulsation therapy

Schirmer's I test was performed and revealed values of 30 mm in the right eye and 28 mm in the left eye, whereas Schirmer's II test reported 12 mm and 14 mm of wetting in the right and left eyes, respectively. The TBUT was found to be >10 s in both eyes with no significant fluorescein staining of the cornea. He reported an OSDI of 12.5.

In consideration of the irregularity of the epithelial surface, we decided to run a diagnostic panel on the tears collected with the help of Schirmer's strips. The panel revealed significantly elevated levels of MMP-9 along with elevation of most of the other pro-inflammatory markers [[Fig. 5b](#)]. We decided to perform a procedural dry eye therapy in the form of vector pulsation therapy for this patient. The biomarker analysis was repeated after 3 weeks and revealed significantly reduced levels of most inflammatory markers [[Fig. 5c](#)]. Considering the reduced levels, we decided to go ahead with the proposed refractive surgery.

c. Severe elevation (>6 times of healthy controls)

In patients with markedly elevated MMP-9 levels and an exceedingly inflamed ocular surface with multiple deranged markers, we recommend a combined approach-vector pulsation therapy, followed by another session of IPL + LLLT spaced over a period of 1 week. Repeat assessment of

markers after the completion of these treatments would then guide the prescription of topical therapy as per the protocol.

The role of vector pulsation therapy has been illustrated with an example earlier. IPL + LLLT has also shown promising results in terms of lowering levels of MMP-9, IL-1 β , IL-17F, MMP-9/ Tissue inhibitor matrix metalloproteinase 1 (TIMP1) ratio, and IL-6, along with improved dry eye parameters sustained over a period of 6 months.

To exemplify this, we present the case of a 35-year-old gentleman, who presented to our dry eye clinic with complaints of burning sensation, grittiness, and eye strain for the past year. He had no known systemic or ocular illnesses or allergies. He had been receiving treatment in the form of lubricating eye drops (carboxymethylcellulose 0.5%, sodium hyaluronate 0.1%) and even immunomodulator eye drops (cyclosporine 0.05%) with no relief in symptoms.

His visual acuity was 6/6 in each eye, with a normal slit-lamp and fundus examination. Dry eye examination was also reported normal—with Schirmer’s 1 of 30 in the right eye and 32 in the left eye, Schirmer’s 2 value of 25 in both the eyes, and TBUT of 9 s and 10 s in the right and left eye, respectively. However, OSDI revealed his subjective symptoms to be significant, with a reported value of 70.62. The patient had evidence of meibomian gland disease. To understand whether his symptoms were purely psychosomatic in origin, we decided to perform a tear biomarker test to rule out any abnormalities in the same. The tear report revealed high values of MMP-9, along with raised ICAM-1 and IL-1b [Fig. 6a].

Test Parameter	Results		Test Parameter	Results	
	Right Eye	Left Eye		Right Eye	Left Eye
IL- 6	231	29.4	IL- 6	414	24.9
IL- 1b	61.6	9.7	IL- 1b	8.01	5.68
IL – 17 A	49.3	36.1	IL – 17 A	40.4	21.7
MMP 9	329180	46807	MMP 9	4355	7033
I CAM – 1	82062	34729	I CAM – 1	46929	40255
TNF - a	20.6	9.61	TNF - a	12.7	7.74
IL-10	0.387	0	IL-10	2.83	0.076
VEGF- A	4883	3164	VEGF- A	2263	2164

Figure 6

(a). Biomarker report showing high levels of MMP-9, Il-1 β , and ICAM-1 in a patient with no clinical evidence, but severe symptoms of dry eye, possibly indicating a subclinical form of dry eye. (b). Biomarker report showing reduced levels of most of the previously elevated markers, along with a rise in the anti-inflammatory IL-10 levels post intense pulsed light and low-level light therapy, indicating a possible role of these markers in the genesis of the patient's symptoms

After a single session of IPL + LLLT, we discovered dramatically lowered levels of most inflammatory mediators after 3 weeks of therapy.

Interestingly, the levels of the anti-inflammatory marker IL-10 had also risen [[Fig. 6b](#)]. The patient had also improved symptomatically and was then continued on a maintenance course of lubricating eye drops. A longer follow-up may be helpful in monitoring the reduction of all markers.

2. Elevated ICAM-1 (>matched control cohort)

We recommend that these patients be treated with a combination of lifitegrast 5% ophthalmic solution for a minimum of 3 months before reassessment.

Ocular surface inflammation is thought to result from the localization of T cells at the surface with subsequent liberation of cytokines, and this localization results from the binding of LFA-1 expressed on T cells to the ICAM-1 expressed on the inflamed epithelium. Lifitegrast is a T-cell integrin antagonist that was developed to mimic ICAM-1, thereby blocking any interaction between LFA-1 and ICAM-1. Clinical trials have demonstrated the efficacy of lifitegrast eye drops in reducing symptoms and signs of dry eye disease, and this would thus be the ideal choice of treatment in patients with elevated ICAM-1.

3. Elevated MMP-9 and ICAM-1 (>matched control cohort)

We recommend that these patients be treated with a combination of the treatments described above—cyclosporine 0.05% eye drops and lifitegrast 5% ophthalmic solution for a minimum of 3 months before reassessment.

4. Elevated IL-17A and TNF- α (>matched control cohort)

We recommend treating these patients with vector pulsation therapy. We also advocate the use of topical corticosteroid therapy, which has demonstrated significant benefits in an animal model, not only in improving dry eye parameters but also in reducing tear inflammatory cytokine levels such as TNF- α .

To elucidate the role of corticosteroid therapy in the reduction of inflammatory cytokines and their clinical sequelae, we present the case of a 26-year-old lady who first presented to us with complaints of blurring of vision in both eyes. She had undergone photorefractive keratectomy (PRK) 6 months before presentation and had been diagnosed as a case of post-PRK haze. The slit-lamp examination revealed anterior stromal haze encroaching the pupillary, which was reflected in the densitometry screening on Pentacam [Fig. 7a and b].

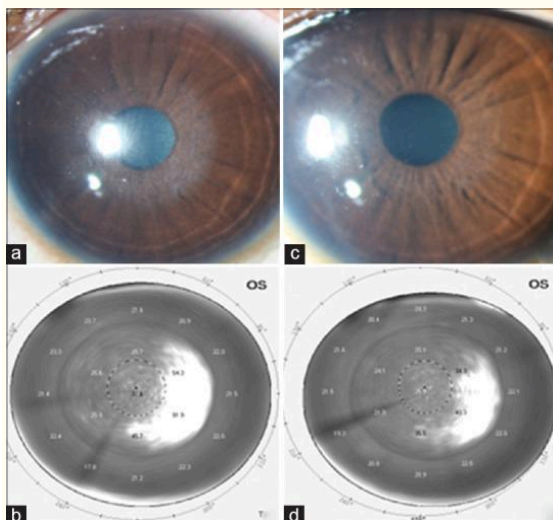


Figure 7

(a). Slit-lamp image of the left eye of a patient who, having undergone photorefractive keratectomy, had developed visually significant anterior stromal haze involving the pupillary area. (b). Increased densitometry values in the area of the clinical appearance of corneal haze. (c). Slit-lamp image of the same patient showing a significantly decreased clinical appearance of anterior stromal haze in response to 4 weeks of corticosteroid therapy in tapering doses. (d). Reduction in the densitometry values corresponding to the decreased density of corneal haze in the patient

We decided to investigate if any factors in the tear film may have contributed to the development of haze. Tear biomarker analysis revealed significantly elevated TNF- α and borderline levels of other inflammatory markers [Fig. 8a]. Given the role of TNF- α as a predictive factor of postoperative haze, she was prescribed corticosteroid therapy (prednisolone acetate 1% suspension) in tapering doses for 4 weeks, along with adequate lubrication. The post-treatment clinical examination revealed significantly reduced density of the corneal haze, both on slit-lamp examination and imaging [Fig. 7c, 7d].

Reassessment of biomarker levels revealed significantly lowered TNF- α levels after 1 month of treatment [Fig. 8b].

Test Parameter	Results		Test Parameter	Results	
	Right Eye	Left Eye		Right Eye	Left Eye
IL- 6	11.2	7.2	IL- 6	11.12	6.32
IL- 1b	6.4	2.83	IL- 1b	6.21	1.83
IL - 17 A	5.67	4.87	IL - 17 A	2.86	3.19
MMP 9	23245	16789	MMP 9	11235	10986
I CAM - 1	29810	32982	I CAM - 1	20345	14657
TNF - a	23.67	21.8	TNF - a	2.64	1.82
IL-10	0.223	0.192	IL-10	0.126	0.082
VEGF- A	223	209	VEGF- A	218	189

Figure 8

(a). Biomarker report of the same patient showing elevated levels of TNF- α , which has been identified as a predictive preoperative factor in the development of postoperative haze. (b). Biomarker report showing reduced levels of TNF- α after 1 month of treatment with tapering doses of topical prednisolone acetate 1%, with the effect of the drug also being reflected clinically in a decreased appearance of corneal haze

5. Elevated IL-6 and IL-1 β (>matched control cohort)

We recommend treating these patients with IPL + LLLT, given the established role of this form of therapy in lowering these markers.

6. In the event of significant symptoms without any abnormal elevation of biomarkers, it is recommended to employ appropriate imaging technology, such as confocal microscopy, to rule out neuropathic corneal pain.

Follow-Up and Reassessment

In patients with mild-to-moderate inflammation prescribed topical therapy, it is advisable to review them after a period of 3 to 6 months for repeat assessment of biomarkers. In case of good response to therapy, the active drug may be tapered and the patient may be continued on lubricating eye drops, whereas in the case of worsening of inflammation, an alternative approach must be sought as per the protocol. In patients with severe inflammation requiring a form of procedural therapy, it is recommended to reassess the patient after 2 weeks to decide further course of topical therapy as per protocol.

Conclusion

With technological advances, increased scope of scientific and clinical research, and non-invasive methods of sampling, tear fluid analysis is an

attractive option not only for diagnosis of disease but also for monitoring progression and guiding the course of treatment. With the incorporation of more biomarkers on our diagnostic panel, we aim to expand the scope of our research to include systemic inflammatory conditions as well. Through this article, we attempt to highlight the manner in which our customized biomarker kit may serve to streamline treatment approaches for ocular surface conditions and enhance patient outcomes. With further developments in the fields of proteomic, lipidomic, and metabolomic detection, it promises to facilitate a convenient, cost-effective, and clinically operable manner toward individualized care. This target-based approach is a deliberate step toward predictive, preventive, and personalized medicine in the near future. At present, our approach is based on individual case examples enlisted herein. A study cohort with a larger sample size may be needed to further validate these findings and establish the efficacy of the protocol described, and this remains a limitation of the study.

Access the exact URL :

<https://www.ncbi.nlm.nih.gov/pmc/articles/PMC10276672/>